

ORIGINAL RESEARCH

Sixteen Infants with Acid Reflux and Colic Undergoing Upper Cervical Chiropractic Care to Correct Vertebral Subluxation: A Retrospective Analysis of Outcome

Erin Elster D.C.¹

Abstract

Objective: The objective of this article is to explore the diagnosis and treatment of trauma-induced injury to the upper cervical spine through the use of protocol developed by the International Upper Cervical Chiropractic Association (IUCCA) and to investigate the potential for improving and eliminating colic and acid reflux through the correction of upper cervical injury. Data from 16 infants who presented with upper cervical injuries and received care according to the above protocol are reviewed.

Clinical Features: Each patient was examined and cared for in my private practice in a non-experimental environment without control subjects. The 16 infants were diagnosed by their physicians with acid reflux (9 infants) or colic (7 infants). Ten of the 16 mothers reported difficulty in their child's birth (mechanical forces) that could have caused upper cervical injuries, such as the use of vacuum extraction or the wrapping of the umbilical cord around the infant's neck.

Intervention and Outcome: Two diagnostic tests, paraspinal digital infrared imaging and laser-aligned cervical radiography, were performed according to IUCCA protocol. These tests objectively identify trauma-induced upper cervical subluxations (misalignments of the upper cervical spine from the neural canal) and resulting neuropathophysiology. Upper cervical subluxations were found in all 16 infants and all 16 cases were resolved with IUCCA upper cervical care.

Conclusion: A causal link between birth trauma-induced upper cervical injury and the onset of acid reflux and colic appears to exist. Correcting the injury to the upper cervical spine through the use of IUCCA protocol appears to reverse infantile colic and acid reflux. Further study in a controlled, experimental environment with a larger sample size is recommended.

Key Indexing Terms: *upper cervical spine, chiropractic, colic, acid reflux, birth trauma, thermography, subluxation*

Introduction

The 16 infants were examined and cared for in my private practice in a non-experimental environment without control subjects. This paper does not purport to be a controlled

research study, but rather serves to provide a foundation for future research. The specific procedure utilized with these patients was developed by the International Upper Cervical Chiropractic Association (IUCCA).¹ Whether the results

1. Private Practice – Boulder, CO

detailed in this report could be reproduced with another chiropractic technique is unknown and is an area for further research. Patients with other conditions such as Parkinson's disease, Multiple Sclerosis, Bipolar Disorder, Tourette Syndrome, Migraine headaches, and vertigo also responded favorably to IUCCA upper cervical chiropractic intervention.²⁻⁶ In these cases, many patients reported experiencing traumas to the head and/or neck prior to the onset of symptoms and diagnoses.

Clinical Features

The parents of sixteen infants with colic or acid reflux consented to their child's examination and treatment in my private practice. Patient data (diagnoses, gender, age, weeks since diagnosis, number of weeks of treatment to resolve the case, parents' recollection of birth trauma, etc.) were compiled and listed in Tables 1 and 2.

Of sixteen infants, seven with colic and nine with acid reflux were examined and treated. Patients ranged in age from two weeks to eleven months. All patients had been diagnosed by their physicians.

Parents were questioned as to whether trauma occurred during their child's birthing process.⁷⁻¹¹ Parents recalled difficulty and/or trauma in 10 of the 16 cases including the abnormal presentation of the child (breech), the use of vacuum extraction, the umbilical cord was wrapped around the infant's neck, and the infant was 'stuck in the birth canal' necessitating an emergency Cesarean section, etc. (Tables 1 and 2).

Intervention

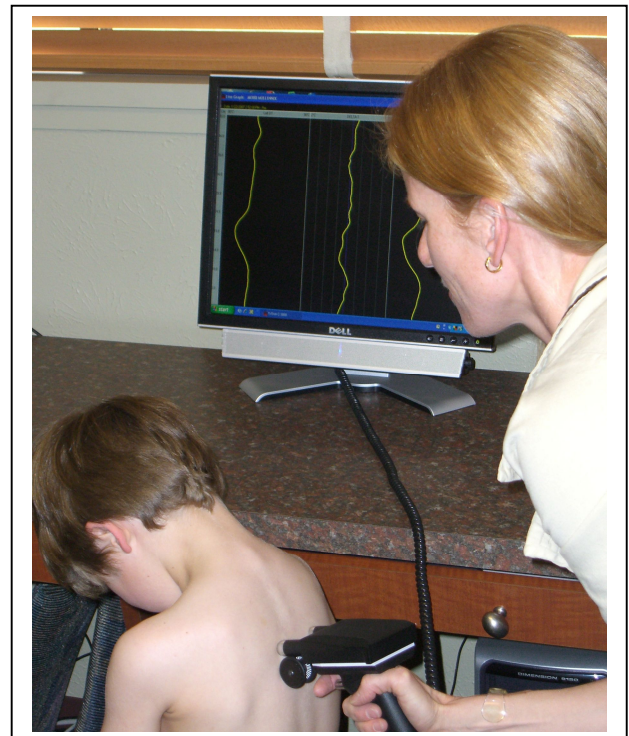
Each patient was examined and cared for utilizing protocol developed by the International Upper Cervical Chiropractic Association (IUCCA).¹ The care is based on the original upper cervical chiropractic research performed by Palmer eighty years ago.¹²⁻¹⁵ It should be noted that there are several chiropractic techniques that focus upon the cervical spine; however, only the technique used in these cases will be discussed in this report. To illustrate the examination and treatment procedures, a single case is detailed below.

An 11-month-old male infant (Case #1, Table 1) attended an upper cervical chiropractic evaluation appointment with his mother, who recalled his health history. While she did not specifically recall any abnormalities with his birth, she noted that since birth her son seemed uncomfortable turning his neck to the left and by two weeks of age, he began passing blood in his stool. At three weeks of age, he was diagnosed with acid reflux and was prescribed Zantac. She reported that he had frequent problems with spitting up, projectile vomiting, excessive irritability and crying, and inability to sleep past an hour or two. In addition, she advised that since birth he had never slept through the night and that he seemed to be experiencing constant pain. Despite daily medication use (Zantac twice per day), the infant's symptoms continued and both the infant and mother were exhausted from sleep deprivation. When the infant was 11 months old, his mother sought help from upper cervical chiropractic care.

After the patient's medical history was recorded, his

evaluation was performed in accordance with the guidelines of the IUCCA through their Applied Upper Cervical Biomechanics (AUCB) program.¹ A paraspinal thermal analysis was performed with the Tytron C-5000 (Figure 1- Titronics Research and Development) from the level of C7 to the occiput according to thermographic protocol.¹⁴⁻¹⁶ Paraspinal digital infrared imaging, which measures cutaneous infrared heat emission, is a form of thermography, a neurophysiological diagnostic imaging procedure. Thermography has been established in chiropractic as a practical and sensitive test for spinal nerve root irritation, articular facet syndromes, peripheral nerve injuries, sympathetic pain syndromes, and the vertebral subluxation complex.¹⁷⁻¹⁹

Figure 1



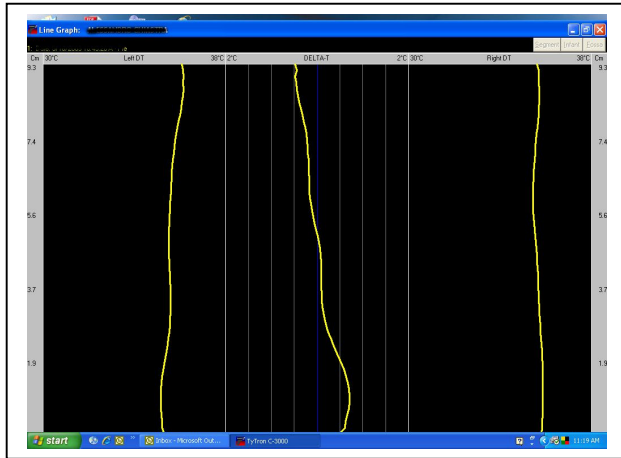Since the amount of blood passing through the skin is directly controlled by the sympathetic nervous system (through control of dilation or constriction of blood vessels), the temperature of any one area of the skin reflects the neurological control of that area. Normal or abnormal skin temperature then becomes an indicator of normal or abnormal neurological function. In blind studies comparing thermographic results to that of CAT scan, MRI, EMG, myelography, and surgery, thermography was shown to have a high degree of sensitivity (99.2%), specificity (up to 98%), predictive value, and reliability.²⁰⁻²²

Thermography has been effective as a diagnostic tool for breast cancer, repetitive strain injuries, headaches, spinal problems, TMJ conditions, pain syndromes, arthritis, and vascular disorders, to name a few.²³⁻³² A limited number of articles have been published demonstrating the use of paraspinal thermal imaging as an integral part of upper cervical protocol, including reports of patients with

Parkinson's disease, Multiple Sclerosis, Migraine headaches, Tourette syndrome, vertigo, and Bipolar disorder.²⁻⁶

Compared to established normal values for the cervical spine, the subject's paraspinous scans contained thermal asymmetries of 0.5°C. (Figure 2) According to cervical thermographic guidelines, thermal asymmetries of 0.5°C or higher indicate abnormal autonomic regulation or neuropathophysiology.³³⁻³⁶

Figure 2



In addition to revealing thermal asymmetries, the subject's scans displayed static thermal differences, thus, a thermal "pattern" was established. "Pattern analysis" of paraspinous temperatures, first developed by Palmer, has received increased attention in chiropractic research.^{12-13, 37-47}

Because upper cervical misalignments were suspected in this patient, a precision upper cervical radiographic series was performed.⁴⁸ The x-ray equipment included a laser-aligned frame (Figure 3- American X-ray Corporation) to eliminate image distortion. In addition, the patient was aligned to the central ray using a laser (Titronics Research and Development) mounted on the x-ray tube. While patients typically would be placed in a positioning chair using head clamps, this is not possible with infants, so supine table films were taken. The two views - lateral and anterior-posterior open mouth - enabled examination of the upper cervical spine in two dimensions: sagittal and transverse. Analysis of the two views was directed towards the osseous structures (foramen magnum, occipital condyles, atlas, and axis) that are intimately associated with the neural axis.⁴⁸ Right laterality of atlas was found (Figure 4).

Figure 3

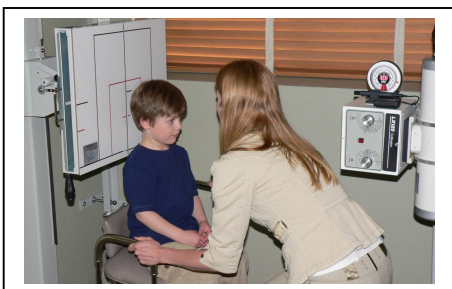
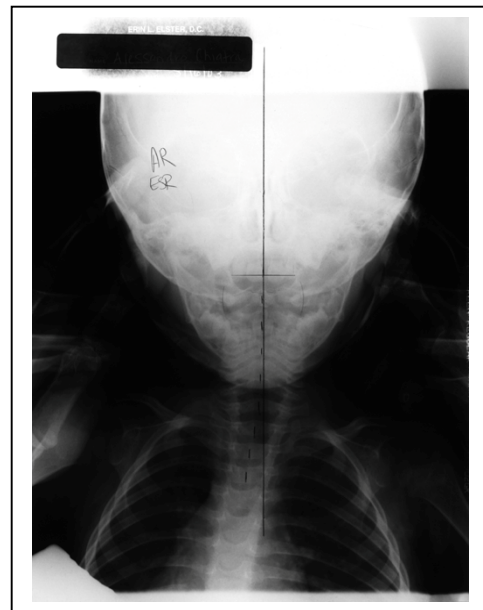
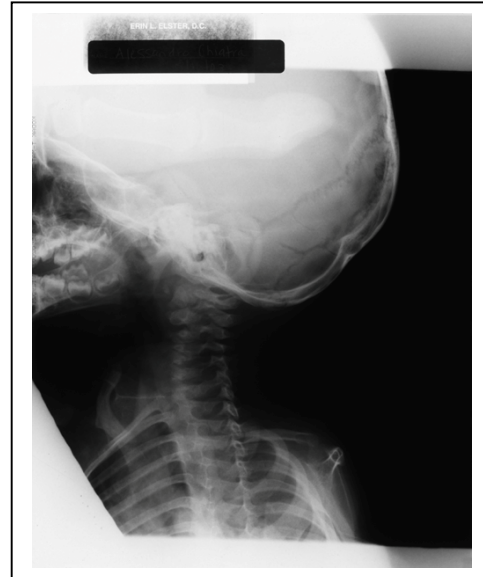

Figure 4

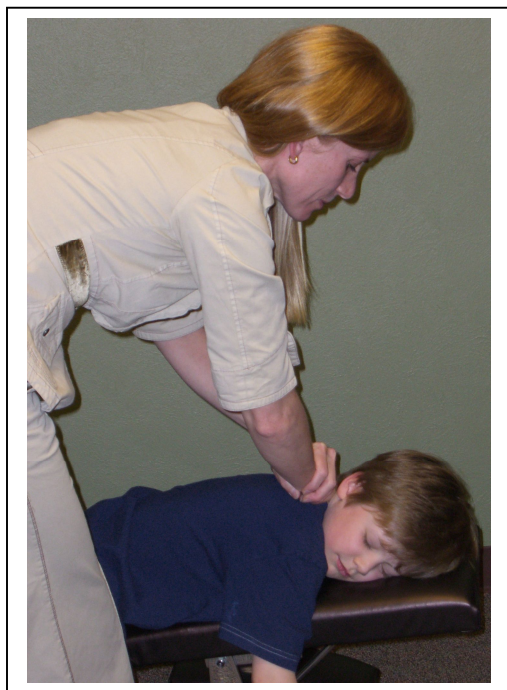

In accordance with AUCB upper cervical protocol, the two criteria used to determine subluxation in this case were thermal asymmetry (measured by paraspinous thermal imaging) and vertebral misalignment (measured by cervical radiographs). Because both criteria (0.5°C thermal asymmetry and right laterality of atlas) were met, a care plan was discussed with the patient's mother. In addition, it was recommended that the subject continue his medical treatment and medications unless otherwise advised by his physician.

Following the parent's consent, chiropractic care began with an adjustment to correct the right laterality of atlas. To administer the adjustment, the infant was placed on a knee-chest table with his head turned to the right (Figure 5). The knee-chest posture was utilized because of the accessibility of the anatomy to be corrected. Using the right posterior arch of

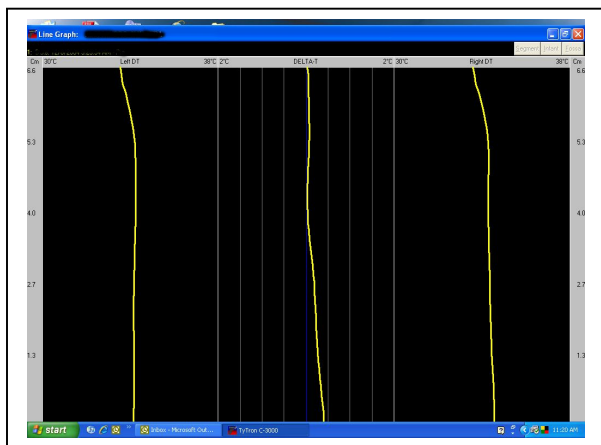
atlas as the contact point, an adjusting force was introduced by hand (only a slight pressure is utilized for infants compared to the adjusting force for an older child or adult).⁴⁹

Figure 5



Next, the patient was placed in a post-adjustment recuperation suite for fifteen minutes as per thermographic protocol.¹⁴⁻¹⁶ After the recuperation period, a post-adjustment thermal scan was performed. The post-adjustment scan revealed a thermal difference of only 0.1°C, which was considered normal according to established cervical thermographic guidelines (compared to the pre-adjustment differential of 0.5°C). Therefore, resolution of the patient's presenting thermal asymmetry (elimination of the thermal "pattern") was achieved (Figure 6).

Figure 6



According to IUCCA protocol, all subsequent office visits began with a thermal scan. An adjustment was administered only if the patient's presenting thermal asymmetry ("pattern") returned. If an adjustment were given, a second scan was performed after a fifteen-minute recuperation period to determine whether restoration of normal thermal symmetry had occurred. This subject's office visits occurred one time per week for the first two weeks of care and once per month for the following two months.

After the infant's first upper cervical adjustment, his mother brought him for a second office visit the following week. His infrared scan showed thermal symmetry so no adjustment was performed. His mother reported a marked improvement in his condition over the previous week. She stated that he had slept better throughout the week and that he could turn his head to both sides. In addition, the reflux symptoms had greatly improved so she was able to discontinue her son's medication.

The next check-up appointment occurred six weeks later after the family had returned from a summer vacation. The infant's thermal scan showed thermal symmetry was still present so no adjustment was administered. His mother reported that her son had slept consistently well throughout the past six weeks and that he often slept through the night; he continued to turn his head freely to both sides; all acid reflux signs and symptoms were absent; and no medications were used. It was recommended that the infant attend a final check-up appointment in one additional month.

One month later (12 weeks after the initial upper cervical adjustment), the infant's mother reported that she had been involved in a motor vehicle accident the previous week with her son who had been in his infant car seat. She stated that she and her son were rear-ended at approximately 40 mph and while her son seemed completely healthy and happy, she was concerned the accident might have disturbed his cervical alignment. A thermal scan was performed, which was normal, so once again, no adjustment was administered. Accordingly, it was recommended that no further treatment was necessary at this time and that the infant's case was resolved. His mother was instructed that if her son had any return of symptoms, any new health complaints, or if he sustained any new traumas to his head, neck, or spine, that she should bring him for an upper cervical check-up appointment.

Four months later, she called to arrange an appointment for her son. She reported that her son's health was normal and that he had not experienced any traumas, but that she wanted to have a routine check-up performed. His thermal scan showed normal thermal symmetry so no adjustment was administered. She reported that her son's symptoms remained absent and no medications were required. During the upper cervical treatment (only one adjustment was performed), no other intervention was reported that could have provided an alternative explanation for the improvement of the patient's condition.

The additional 15 patients were examined and cared for utilizing the same IUCCA protocol detailed above, including the use of paraspinal digital infrared imaging, laser-aligned upper cervical radiography, knee-chest adjusting procedure, and post-adjustment recuperation. Upon examination with

paraspinal digital infrared imaging, all patients showed static thermal asymmetry of at least 0.5°C, or thermal “pattern”. (Tables 1 and 2) In addition, all patients’ laser-aligned cervical radiographs showed upper cervical deviation from the neural axis. On average, each patient’s atlas deviated from the foramen magnum (occiput) laterally (to the left or right) five millimeters or less. (Tables 1 and 2) While parents recalled difficulty and/or trauma during their child’s birthing process in 10 of the 16 cases, all 16 presented with upper cervical injuries.

Because upper cervical subluxations were discovered in all patients, it was recommended that each of these infants receive care to correct their cervical injuries. Before initiating care, patients were advised to continue medical treatment including medications unless otherwise advised by their physicians. After consent was obtained, care was administered according to IUCCA protocol.

Outcome

Outcomes of the 16 cases are illustrated in Tables 1 and 2. From a total of 16 cases, 100% of patients were symptom-free following upper cervical chiropractic care. Two to eight weeks of treatment were required for symptomatic resolution.

Conclusion

Sixteen infants with colic or acid reflux were evaluated and cared for using protocol developed by the International Upper Cervical Chiropractic Association (IUCCA). Histories of birth trauma were recalled in 10 cases; upper cervical subluxations were found in all 16 cases; and 100% of the cases responded to care with symptoms completely resolved. These results suggest a causal link between birth trauma, upper cervical injury, and colic / acid reflux onset. Correcting the injury to the upper cervical spine through the use of IUCCA protocol appears to eliminate colic and acid reflux. Further study in a controlled environment with a larger sample size is recommended.

Acknowledgements

The author gratefully acknowledges Drs. William Amalu and Louis Tiscareno of the International Upper Cervical Chiropractic Association (IUCCA) for their Applied Upper Cervical Biomechanics Course and the Titronics Corporation for the Tytron C-3000 Paraspinal Digital Thermal scanner.

References

1. Applied Upper Cervical Biomechanics program. www.pacificchiro.com. Redwood City, California: International Upper Cervical Chiropractic Association, 1993.
2. Elster E. Eighty-one patients with Multiple Sclerosis and Parkinson’s disease undergoing upper cervical chiropractic care to correct vertebral subluxation: a retrospective analysis. *Journal of Vertebral Subluxation Research*. 2004 Aug.
3. Elster E. Treatment of bipolar, seizure, and sleep disorders and migraine headaches utilizing a chiropractic technique. *J Manipulative Physiol Ther*.

- 2004 Mar-Apr;27(3):E5.
4. Elster E. Upper cervical chiropractic care for a nine-year-old male with tourette syndrome, attention deficit hyperactivity disorder, depression, asthma, insomnia, and headaches: a case report. *Journal of Vertebral Subluxation Research*. 2003 July.
5. Elster E. Upper cervical chiropractic care for a patient with chronic migraine headaches with an appendix summarizing an additional 100 headache cases. *Journal of Vertebral Subluxation Research*. 2003 Aug.
6. Elster E. Sixty patients with chronic vertigo undergoing upper cervical chiropractic care to correct vertebral subluxation: a retrospective analysis. *Journal of Vertebral Subluxation Research*. 2006 Nov.
7. Phelan JP, Ahn MO. Perinatal observations in forty-eight neurologically impaired term infants. *Am J Obstet Gynecol* 1994 Aug; 171(2):424-31.
8. Banks BD, Beck RW, Columbus M. Sudden infant death syndrome: a literature review with chiropractic implications. *J Manipulative Physiol Ther* 1987 Oct; 10(5): 246-52.
9. Gottlieb MS. Neglected spinal cord, brain stem and musculoskeletal injuries stemming from birth trauma. *J Manipulative Physiol Ther* 1993 Oct; 16(8):537-43.
10. Ratner AI, Marulina VI. Clinical picture and diagnosis of a myotonic syndrome in children resulting from birth injury. *Zh Nevropatol Psikhiatr Im S S Korsakova* 1981; 81(10):1461-6.
11. Tobin A. Latent spinal cord and brain stem injury in newborn infants. *Develp. Med. Child. Neurol*. 1969;11, 54-68.
12. Palmer BJ. *The Subluxation Specific The Adjustment Specific*. Davenport, Iowa: Palmer School of Chiropractic, 1934: 862-70.
13. Palmer, BJ. *Chiropractic Clinical Controlled Research*. Davenport, Iowa: Palmer School of Chiropractic, 1951.
14. International Thermographic Society. *Thermography protocols*. In: Amalu W, Tiscareno L. *Clinical neurophysiology and paraspinal thermography: module 2—applied upper cervical biomechanics course*. Redwood City, Calif: International Upper Cervical Chiropractic Association; 1993. p.67-70.
15. American Academy of Thermology. *Thermography Protocols*. In: Amalu W, Tiscareno L. *Clinical neurophysiology and paraspinal thermography: module 2—applied upper cervical biomechanics course*. Redwood City, Calif: International Upper Cervical Chiropractic Association; 1993. p.67-70.
16. American Academy of Medical Infrared Imaging. *Thermography Protocols*. In: Amalu W, Tiscareno L. *Clinical neurophysiology and paraspinal thermography: module 2—applied upper cervical biomechanics course*. Redwood City, Calif: International Upper Cervical Chiropractic Association; 1993. p.67-70.
17. Amalu W, Tiscareno L, et al. *Clinical neurophysiology and paraspinal thermography: module 2- Applied Upper Cervical Biomechanics Course*. Redwood City, Calif: International Upper Cervical Chiropractic Association, 1993. p.62-70.

18. Amalu W, Tiscareno L. Objective analysis of neuropathophysiology, Part 1. *Today's Chiropractic* 1996 May; 25(3): 90-6.
19. Amalu W, Tiscareno L. Objective analysis of neuropathophysiology, Part 2. *Today's Chiropractic* 1996 July; 25(4): 62-66.
20. Goldberg G. Thermography and magnetic resonance imaging correlated in 35 cases. *Thermology* 1986; 1: 207-11.
21. Thomas D, Cullum D, Siahhamis G. Infrared thermographic imaging, magnetic resonance imaging, CT scan and myelography in low back pain. *Br J Rheumatol* 1990; 29: 268-73.
22. Weinstein SA, Weinstein G. A clinical comparison of cervical thermography with EMG, CT scanning, myelography and surgical procedures in 500 patients. *Proceedings of the 1st annual meeting of the Academy of Neuromuscular Thermography*; 1985 May. *Postgrad Med* 1986; Special ed: 44-6.
23. Gros C, Gautherie M. Breast thermography and cancer risk prediction. *Cancer* 1980; 45(1): 51-56.
24. Diakow P. Thermographic imaging of myofascial trigger points. *JMPT* 1988; 11(2): 114-17.
25. Drummond PD, Lance JW. Thermographic changes in cluster headaches. *Neurology* 1984; 34:1292-98.
26. Hender N, Uematsu S. Thermographic validation of physical complaints in psychogenic pain patients. *Psychosomatics* 1982:23.
27. Zellner J, Bandler H. Thermographic assessment of carpal tunnel syndrome. *J Bone Joint Surg* 1986; 10: 558.
28. Weinstein SA, Weinstein G. A protocol for the identification of temporomandibular joint disorder by standardized computerized electronic thermography. *Clin J Pain* 1987; 3: 107-12.
29. Sionni, IH. Thermography in suspected deep venous thrombosis of lower leg. *Europ J Radiol* May 1985; 281-84.
30. Ecker A. Reflex sympathetic dystrophy thermography in diagnosis. *Psychiatric Annals* 1984; 14(11): 787-93.
31. Swerdlow B, Dieter JN. The persistent migraine cold patch and the fixed facial thermogram. *Thermology* 1986; 2:1620.
32. Wood EH. Thermography in the diagnosis of cerebrovascular disease. *Radiology* 1965; 85: 270-83.
33. Uematsu, E, et al. Quantification of thermal asymmetry, part 1: normal values and reproducibility. *J Neurosurg* 1988; 69: 552-555.
34. Feldman F, Nicoloff E. Normal thermographic standards in the cervical spine and upper extremities. *Skeletal Radiol* 1984; 12: 235-249.
35. Clark RP. Human skin temperatures and its relevance in physiology and clinical assessment. In: Francis E, Ring J, Phillips B, et al. *Recent advances in medical thermology*. New York: Plenum Press, 1984, 5-15.
36. Uematsu S. Symmetry of skin temperature comparing one side of the body to the other. *Thermology* 1985; 1:4-7.
37. Hart, J.F., Boone, W.R. *Pattern Analysis of Paraspinal Temperatures: A Descriptive Report*. *Journal of Vertebral Subluxation Research* 2000; 3(4).
38. Kent C. Paraspinal skin temperature differentials and vertebral subluxation. *The Chiropractic Journal*. September 1997.
39. Schram SB, Hosek RS, Owens ES. Computerized paraspinal skin surface temperature scanning: A technical report. *J Manip Physiol Ther* 1982; 5(3): 117-122.
40. Ebrall PS, Iggo A, Hobson P, Farrant G. Preliminary report: The thermal characteristics of spinal levels identified as having differential temperature by contact thermocouple measurement (Nervo Scope). *Chiropr J of Australia* 1994; 24(4):139-143.
41. Stewart MS, Riffle DW, Boone WR. Computer-aided pattern analysis of temperature differentials. *J Manip Physiol Ther* 1989;12(5):345-352.
42. Brand NE, Gizoni CM. Moire contourgraphy and infrared thermography: changes resulting from chiropractic adjustments. *J Manip Physiol Ther* 1982; 5(3): 113-119.
43. DeBoer K, et al. Inter- and intra-examiner reliability study of paraspinal infrared temperature measurements in normal students. *Research Forum* 1985; 2(1):4-12.
44. Plaugher G. Skin temperature assessment for neuromusculoskeletal abnormalities of the spinal column. *J Manip Physiol Ther* 1992;15(6):368.
45. Salminen, B.J., Misra, T. Inter- and Intra-examiner Reliability of the TyTron C-3000. *Abstracts of the Eighth Annual Vertebral Subluxation Research Conference Sponsored by Sherman College of Straight Chiropractic*. *Journal of Vertebral Subluxation Research* 2000; 4(1).
46. Senzon, S.A. *The Theory of Chiropractic Pattern Analysis Based on the New Biology*. *Abstracts of the Eighth Annual Vertebral Subluxation Research Conference Sponsored by Sherman College of Straight Chiropractic*. *Journal of Vertebral Subluxation Research* 2000; 4(1).
47. Hart, J.F. Analyzing the neurological interference component of the vertebral subluxation with the use of pattern analysis: A Case Report. *Abstracts of Association of Chiropractic Colleges Eighth Annual Conference*. *The Journal of Chiropractic Education* 2001; 15(1).
48. Amalu W, Tiscareno L, et al. *Precision Radiology: Module 1 and 5- Applied Upper Cervical Biomechanics Course*. Redwood City, Calif: International Upper Cervical Chiropractic Association, 1993. p.65-84.
49. Amalu W, Tiscareno L, et al. *Precision Multivector Adjusting: Modules 3 and 7- Applied Upper Cervical Biomechanics Course*. Redwood City, Calif: International Upper Cervical Chiropractic Association, 1993. p. 64-73.

Table 1: Case Histories and Examination Findings for Nine Acid Reflux Patients

Patient	Age	Gender	Time Since Diagnosis	History of Birth Trauma	Weeks of Treatment	Thermal Deviation	X-ray Listing	Treatment Results
1	11mo	M	10 mo	None	6 wks	0.5°C	AR	Symptom-free
2	8wks	M	4wks	Vacuum extraction	2 wks	0.7°C	AL	Symptom-free
3	8wks	F	6wks	Forceful extraction	6 wks	0.5°C	AR	Symptom-free
4	5mo	M	5mo	None	8 wks	0.5°C	AR	Symptom-free
5	4wks	F	2wks	Extended labor	8 wks	1.0°C	AL	Symptom-free
6	3wks	M	2wks	None	2wks	0.5°C	AL	Symptom-free
7	3mo	M	1mo	Twin / C-section	4wks	0.6°C	AL	Symptom-free
8	5mo	M	4mo	Twin / C-section	8wks	1.0°C	AR	Symptom-free
9	6wks	M	3wks	Abnormal presentation	2wks	0.8°C	AL	Symptom-free

Table 2: Case Histories and Examination Findings for Seven Colic Patients

Patient	Age	Gender	Time Since Diagnosis	History of Birth Trauma	Weeks of Treatment	Thermal Deviation	X-ray Listing	Treatment Results
10	4wks	M	1 mo	Abnormal Presentation	4 wks	0.6°C	AL	Symptom-free
11	6 mo	M	6mo	None	6 wks	0.6°C	AL	Symptom-free
12	2wks	F	1wks	None	2 wks	1.1°C	AL	Symptom-free
13	4wks	F	1 wk	None	2 wks	0.5°C	AL	Symptom-free
14	5 mo	M	4 mo	Umbilical cord wrapped around neck	6 wks	0.9°C	AL	Symptom-free
15	7wks	M	4wks	Stuck in birth canal-Emergency C-section	6wks	1.1°C	AL	Symptom-free
16	5wks	F	5 wks	Umbilical cord wrapped around neck	2wks	1.3°C	AL	Symptom-free